



The ABC of community emergency care: 3 Chest pain

C Laird, P Driscoll and J Wardrope

Emerg. Med. J. 2004;21;226-232
doi:10.1136/emj.2003.013938

Updated information and services can be found at:
<http://emj.bmj.com/cgi/content/full/21/2/226>

These include:

References

1 online articles that cite this article can be accessed at:
<http://emj.bmj.com/cgi/content/full/21/2/226#otherarticles>

Rapid responses

You can respond to this article at:
<http://emj.bmj.com/cgi/eletter-submit/21/2/226>

Email alerting service

Receive free email alerts when new articles cite this article - sign up in the box at the top right corner of the article

Topic collections

Articles on similar topics can be found in the following collections

[Other accident and emergency medicine](#) (1866 articles)
[Other Cardiovascular Medicine](#) (2112 articles)

Notes

To order reprints of this article go to:
<http://journals.bmj.com/cgi/reprintform>

To subscribe to *Emergency Medicine Journal* go to:
<http://journals.bmj.com/subscriptions/>

3 CHEST PAIN

C Laird, P Driscoll, J Wardrope

226

Emerg Med J 2004;**21**:226–232. doi: 10.1136/emj.2003.013938

Chest pain is the commonest reason for 999 calls and accounts for 2.5% of out of hours calls. Of patients taken to hospital about 10% will have an acute myocardial infarction (AMI). Evidence suggests that up to 7.5% of these will be missed on first presentation. There are a number of other life threatening conditions, which can present as chest pain and must not be overlooked. The objectives of this article are therefore to provide a safe and comprehensive system of dealing with this presenting complaint (box 1).

Box 1 Objectives of assessment of patients with chest pain

- ▶ To undertake a primary survey of the patient and treat any immediately life threatening problems
- ▶ To identify any patients who have a normal primary survey but have an obvious need for hospital admission
- ▶ To undertake a secondary survey considering other systems of the body where dysfunction could present as chest pain
- ▶ To consider a list of differential diagnoses
- ▶ Discuss treatment based on the probable diagnosis(es) and whether home management or hospital admission is appropriate
- ▶ Consider follow up if not admitted

PRIMARY SURVEY

ABC principles

Primary survey—If any of the following present treat immediately and transfer to hospital

- ▶ Airway obstruction
- ▶ Respiratory rate <10 or >29 per minute
- ▶ O₂ sats <93%
- ▶ Pulse <50 or >120
- ▶ Systolic BP <90 mm Hg
- ▶ Glasgow coma score <12

PATIENTS WITH NORMAL PRIMARY SURVEY WITH OBVIOUS NEED FOR HOSPITAL ADMISSION

There are four life threatening medical conditions that can present with chest pain. These are:

- ▶ Acute coronary syndrome (ACS)
- ▶ Massive pulmonary embolus
- ▶ Dissection of the thoracic aorta
- ▶ Tension pneumothorax

The history and a brief examination may lead you to suspect that one of these is the probable diagnosis but often in the early stages, patients may not have significant abnormal physical signs. Nevertheless, urgent hospital admission must be arranged if you suspect any of the above or any other life threatening diagnosis.

In the case of myocardial infarction it should be remembered that 50% of sudden cardiac deaths occur within one hour of the start of a myocardial infarction and 75% within three hours. In addition, the benefits of thrombolysis are directly related to the length of time between the onset of symptoms and its delivery. For both these reasons it is important that if you suspect a myocardial infarction you have immediate access to a defibrillator and can deliver thrombolysis or arrange rapid transportation to a facility where it can be delivered.

See end of article for authors' affiliations

Correspondence to:
Mr C Laird, BASICS Scotland,
Collyhill Lodge, Auchterarder
PH3 1ED, UK;
claird@basics-scotland.org.uk



Figure 1 Defibrillator.

SECONDARY SURVEY (INCLUDING HISTORY TAKING)

Having dealt with the potential life threatening cases you will be left with a group of patients with whom a more thorough clinical examination will be required before considering whether they can be either treated and left at home, or referred elsewhere.

Take a history of the presenting complaint, gather relevant information, and perform an examination (see article 2 in this series and journal web site (<http://www.emjonline.com/supplemental>) on examination).

For patients with chest pain—respiratory, cardiovascular, abdominal, and musculoskeletal examinations are appropriate.



Figure 2 Patient with chest pain.

The following points may be helpful in reaching a diagnosis in a patient presenting with chest pain.

Type of pain

There are three main categories of chest pain that patients present with. These are:

- ▶ Typical cardiac pain
- ▶ Pleuritic chest pain
- ▶ Atypical chest pain

To differentiate these types of pain it is important to differentiate the two broad categories of pain of which patients will complain. These are somatic and visceral. Somatic pain originates from the chest wall (skin, ribs, and intercostal muscles), pericardium (fibrous and parietal layer), and the parietal pleura. Pain from these structures is transmitted to the brain by the somatic nerve fibres that enable the brain to accurately locate the site of the problem. This means the patient may be able to accurately locate the area of pain. In the case of pleuritic chest pain, it will also be specifically related to movements of breathing. Consequently if the patient is asked to take a deep breath they will experience more pain. Visceral pain in contrast originates from the deeper thoracic structures (heart, blood vessels, and oesophagus) and is carried in the autonomic nerve fibres. These give a less precise location of the pain, and the pain is generally described as a discomfort, heaviness, or ache.

Always ask about the relation of the pain to breathing, movement, exercise, and rest.

Progress of symptoms

Gain a detailed impression of how the pain started. Pain that has wakened the patient should be regarded as significant.

Duration of pain

Typical cardiac pain that lasts less than 15 minutes is defined as angina. Acute coronary syndrome pain lasts more than 15 minutes but it would be unusual for it to continue for over 24 hours. Chest pain lasting only a few seconds is unlikely to be cardiac.

Associated symptoms

Inquire if the patient has nausea, vomiting, shortness of breath, sweating, cough, and sputum production. Have they had any leg swelling, injury, or recent surgery?

Previous similar symptoms

A previous history of ischemic heart disease makes it much more probable that the pain is cardiac. However, patients with heart disease do have other chest problems and the patient may say that the pain is different from their usual symptoms.

Risk factors

The presence of risk factors for cardiovascular disease should increase your suspicion as to a cardiac cause for the pain (box 2).

Medical history/drugs allergies

(See article 2 of the series on examination.)

It is important during the history taking to ask the patient about their medical history as they may already have had an

Box 2 Important risk factors for angina or acute coronary syndrome

- ▶ Smoking
- ▶ Hypertension
- ▶ Diabetes
- ▶ Strong family history (that is, ischaemic heart disease onset <60 years)
- ▶ High cholesterol concentrations

illness that could present as chest pain. A drug history is also important, specifically ask about aspirin (you may need to give this), and if they have taken GTN, warfarin, or other cardiac medications.

Social history and substances

(See article 2 of the series on examination.)

Some illegal drugs such as cocaine may cause chest pain. Patients with a history of alcohol misuse or illegal drug use are at increased risk of developing chest infections and suffering from thromboembolic disease.

Examination

(See article 2 of this series on examination.)

Vital signs

Unless you are transporting the patient immediately, always measure a full set of vital signs.

General

Is the patient confused/anxious, short of breath? This indicates a critical situation. Go back to primary survey.

Is the patient obviously in pain? Are they pale/sweaty? Have they been sick? If the answer to any of these questions is positive, there is a greater likelihood of serious disease.

Cardiovascular

Pay special attention to the rate and rhythm of the arterial pulse and the level of the jugular venous pulse. Ask the patient to take a deep breath, look for an increase in pain during inspiration. Follow this by listening to the heart sounds and the lung bases. Finish by examining the ankles, calves, and foot pulses (for oedema/signs of DVT).

Chest wall tenderness reproducing the patient's pain is suggestive of musculoskeletal pain but studies have shown this sign to be present in up to 15% of patients with confirmed myocardial infarction. Therefore this sign on its own should never be used to exclude a myocardial infarction.

Tests

An ECG is indicated in patients with chest pain. Under the age of 30, ischaemic heart disease is uncommon but if the pain is typical, obtain a 12 lead ECG. Detailed interpretation

of the ECG is beyond the scope of this text but readers are referred to the texts in the further reading section at the end of this article. An abnormal ECG in a patient with chest pain is an indication for admission to hospital.

DIFFERENTIAL DIAGNOSIS

Table 1 shows a list of the differential diagnoses classified by the type of pain they present with.

Cardiac pain

Pain arising from the heart may present as either "typical cardiac pain" or "atypical chest pain". The former is described as a central heavy or crushing pain that may radiate to the jaw, neck, shoulder, or arm.

Ischaemic cardiac pain originates from the myocardium when its blood supply is insufficient for its needs. It can be broadly divided into two categories—angina and acute coronary syndrome.

On a clinical basis, angina is arbitrarily defined as lasting less than 15 minutes. It is often related to increased myocardial oxygen demand, for example, stress or exercise. All ischaemic cardiac pain lasting more than 15 minutes, or less than 15 minutes but recurring on a regular basis, is classified as acute coronary syndrome. This includes a variety of conditions including:

- ▶ Infarction with ST elevation (STEMI)—usually progresses to Q wave MI (QMI)
- ▶ MI confirmed but no Q developed (NQMI)—usually no ST elevation either (NSTEMI)
- ▶ MI occurring with left bundle branch block (LBBB) hiding ST elevation
- ▶ ACS *without* serological evidence of MI = unstable angina

Angina is caused by a narrow coronary artery, which at times of increased myocardial oxygen demand cannot supply sufficient blood to the muscle. Unstable angina and NQMI are normally associated with a thrombus partially occluding a coronary artery. These thrombi are unstable and can break off leading to myocardial ischaemia and infarction. ST elevation myocardial infarction (STEMI) is caused by a thrombus completely occluding a coronary artery.

Features of ischaemic cardiac pain**TREATMENT****Angina**

Consider this diagnosis if the pain lasted less than 15 minutes or settles within five minutes of GTN administration and is a single episode. If pain is recurrent, consider it to be acute coronary syndrome and refer. If the patient is young (35–70) and this is the first episode of typical ischaemic pain and has come on at rest, refer even with one episode.

Table 1 Differential diagnoses

Cardiac ischaemic pain	Pleuritic pain	Atypical pain
Angina	Pneumonia	Non-specific chest pain
Acute coronary syndrome (Dissecting aortic aneurysm)	Pulmonary embolism	Oesophageal pain
(Oesophageal pain) (pericarditis)	Pneumothorax	Cardiac pain
	Rib injury (pericarditis)	Gastric/biliary pain
		Chest wall pain
		Pericarditis
		Dissecting aortic aneurysm

Features of ischaemic cardiac pain

- ▶ Precipitated by exertion
- ▶ Radiation of pain to jaw, neck, shoulder, or arm
- ▶ Relieved by GTN
- ▶ Previous history of similar pain relieved by rest or GTN
- ▶ History of ischaemic heart disease
- ▶ Age (unusual less than 35 years but not impossible)
- ▶ Risk factors—a history of smoking, hypercholesterolaemia, hypertension, diabetes mellitus, or a family history of ischaemic heart disease in relatives under 60 years

Myocardial infarction

Initial/general—carry out a full ABC assessment and provide oxygen and analgesia (appropriate to the diagnosis). A defibrillator must be taken to any patient complaining of chest pain.

JRCALC MI management

- ▶ Administer 400 µg GTN where systolic BP is estimated >90 mm Hg
- ▶ Give high flow oxygen via a non-rebreathing mask
- ▶ Where appropriate move to the ambulance at this stage
- ▶ If pain persists consider a second dose of 400 µg GTN where systolic BP is estimated >90 mm Hg
- ▶ Give aspirin 300 mg orally
- ▶ Obtain intravenous access if not already achieved
- ▶ Monitor BP for hypotension and position patient appropriately
- ▶ If pain continues, morphine 2.5 mg–10 mg intravenously may be administered (nalbuphine 10–40 mg may be given as an alternative)
- ▶ Pain assessment scoring should be carried out before and after analgesia has been administered
- ▶ **Remove to nearest suitable receiving hospital without delay for urgent thrombolytic therapy**

Empowerment

- If trained in thrombolysis then
- ▶ Ensure the patient has the indications (typical chest pain+appropriate ST elevation; LBBB)
 - ▶ Ensure the patient has no contraindications
 - ▶ Explain risks and benefits
 - ▶ Obtain consent and administer thrombolysis

Who can be left at home?

Consider this option if the patient has a history of angina, and they have had a typical episode lasting less than 15 minutes, they are well and the ECG is normal. They must of course be told to call for assistance if the pain recurs. It is desirable to have a relative or carer stay with them, or to do a check by visit or telephone in a few hours.

Pericarditis

The pericardium is a double layer of tissue, which envelops the heart (fig 3). It has an outer thick, fibrous layer that is attached to the base of the great vessels and the diaphragm. The gap between the heart and this fibrous layer is called the pericardial space. This is covered by a thin, serous layer, which lines the inner surface of the fibrous pericardium as well as the outer surface of the heart. Normally the two

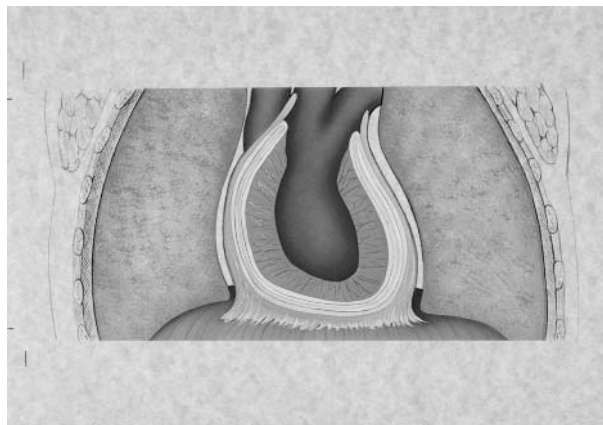


Figure 3 Diagram of the pericardium.

serous layers slide over one another during the movement of the heart, an action facilitated by the small amount of fluid in pericardial space. However, in pericarditis the surfaces become swollen, tender, and inflamed. This usually results from infection but it can result from autoimmune reactions, after myocardial infarction and cardiac surgery.

Pericarditis commonly presents as chest pain described as midline and sharp. The pain is made worse by movement and breathing whereas sitting up and leaning forward may relieve it. The pain may radiate to the back, neck, or left shoulder and is associated with dyspnoea, tiredness, and fever.

Dissecting aortic aneurysm

In this condition blood breaks through the inner lining of the aorta and creates a false passage between the endothelium and the outer wall. In doing so it may occlude the branches of the aorta and give rise to a variety of conditions including strokes. It may also track proximally and burst through into the pericardium or damage the aortic valve. One of the signs of this can be disparity between the upper limb blood pressure recordings.

Typically the patient presents with severe, “ripping/sharp” chest pain radiating through to the back. Diagnosis is difficult but is made easier by thinking of the condition, particularly in those with a higher risk (for example, hypertension or Marfan’s syndrome). Examination may

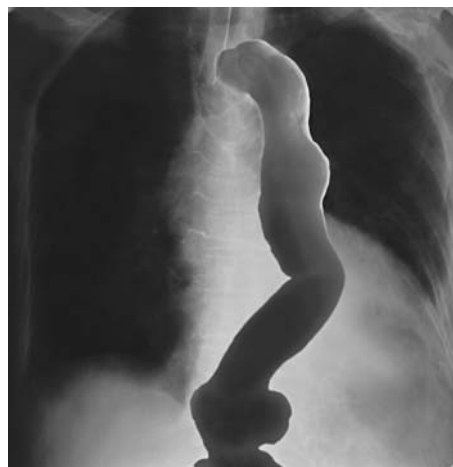

Figure 4 Dissecting aortic aneurysm.

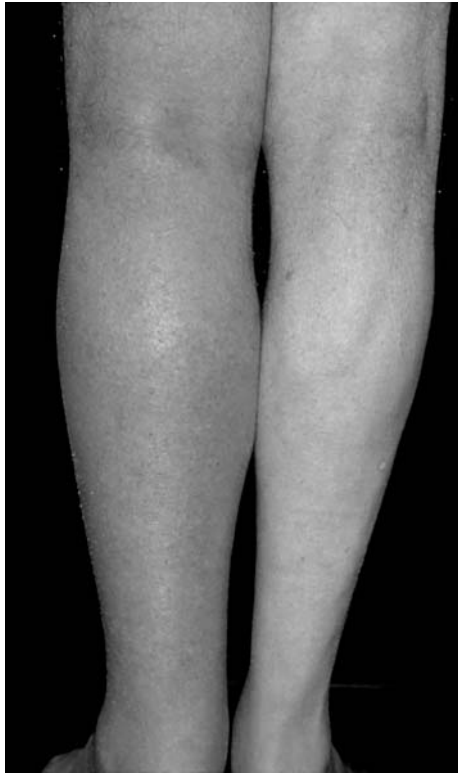

Figure 5 Deep venous thrombosis.

reveal a difference in the blood pressure between the left and right arm. There may be murmurs heard over the back (fig 4).

Patients with ACS, pericarditis, or thoracic aortic dissection will usually have had problems identified in the primary survey. If not, correct any ABC abnormality, give pain relief and arrange immediate admission to hospital.

Cervical root pain

This occurs when one of the nerves that exits the cervical spine is irritated by a structures within the vertebral column.

The pain is limited to the upper chest and the neck and is usually precipitated by neck movement.

These patients will not normally require admission. Treatment will be from the following options: analgesia, non-steroidal anti-inflammatory drugs, muscle relaxants, and a soft cervical collar.

Chest wall pain

This is pain originating from the ribs or chest wall musculature, or both. It may be related to trauma in which case the area of tenderness is at the site of injury. In non-trauma cases, the pain and tenderness are usually over the anterior chest wall.

Treatment is with non-steroidal anti-inflammatory drugs.

If associated with major trauma, patients should be admitted.

Pneumothorax

A pneumothorax is the complete or partial collapse of a lung.

There is usually a sudden onset of sharp chest pain and dyspnoea. The pain is normally one sided and may radiate to the back. Risk factors include obstructive pulmonary disease, trauma, and tall thin young people.

Treat any ABC abnormality and provide oxygen and analgesia. This patient will need to be sent to hospital.

Pulmonary embolism

This occurs when a clot forms within the venous system of the body and then travels to the lungs and obstructs part of the pulmonary circulation (fig 5). The onset of symptoms is sudden, often unilateral and associated with dyspnoea and tachypnoea (respiratory rate >20).

Risk factors include a recent history of trauma or surgery, venous stasis, or hypercoagulability. The pre-test probability of a pulmonary embolism can be predicted from the table 2.

The vital signs may be abnormal and hence the patient will be primary survey positive. If this is not the case, but pulmonary embolism is suspected, appropriate resuscitation should be started, if required, and the patient sent to hospital.

Table 2 Pre-test probability of pulmonary embolism
Well's criteria

Clinical signs of DVT	3.0
Other diagnosis less likely	3.0
HR > 100	1.5
Stasis or operation in $<4/52$	1.5
History of DVT or PE	1.5
Active Ca or treatment in $<6/12$	1.0
Haemoptysis	1.0

Low risk 2 or less; moderate risk 2–6; high risk > 6 .

Infection

The patient may have a history of a current or recent upper respiratory tract infection and a productive cough. On examination there may also be fever and breathlessness.

To make decisions on treatment and whether the patient can be left at home, the following guidelines from The British Thoracic Society should be used:

Admit if:-

Children

- ▶ Oxygen saturation $<92\%$
- ▶ Respiratory rate >50 breath/min, under 1 year 70 breath/min
- ▶ Difficulty in breathing
- ▶ Grunting
- ▶ Signs of dehydration
- ▶ Family not able to provide appropriate observation and supervision
- ▶ Unable to take antibiotics because of vomiting

Adults

- ▶ Confused
- ▶ Oxygen saturation $<92\%$
- ▶ Respiratory rate >30 breath/min
- ▶ Low blood pressure (systolic <90 mm Hg, diastolic < 60 mm Hg)
- ▶ >50 years of age or have coexisting disease
- ▶ Unable to take antibiotics because of vomiting

Treatment

If admission is not planned encourage the patient to rest, drink plenty of fluids, and not to smoke. Pleuritic pain should be treated with simple analgesics.

Amoxicillin is the antibiotic of choice for adults with erythromycin or clarithromycin as an alternative for patients who are hypersensitive to penicillins.

All children under 1 year should be examined by a doctor.

Amoxycillin is the first choice of antibiotic for children under 5. Alternatives are co-amoxiclav, cefaclor, erythromycin, clarithromycin, and azithromycin.

Table 3 Summary of causes and types of chest pain

Aetiology	Type of pain	Sight of pain	Radiation	Duration of pain	Associated symptoms	Mode of onset	ECG findings	Risk factors
Angina	Visceral	Retrosternal	Neck, jaw, shoulder, and arm	>15 min	Nausea and dyspnoea	Variable	ST elevation or depression	
Pericarditis	Somatic	Midline	Neck, back, or shoulder	Hours to days	Pain worse on movement or breathing	Variable	ST elevation in all leads except aVR and V1	Viral infection, recent MI trauma, post-cardiac surgery
Dissecting aortic aneurysm	Visceral severe	Retrosternal	Interscapular	Variable	Nausea and breathlessness May be exacerbated by neck movement	Sudden	Non-specific	History of hypertension
Cervical nerve root pain	Sharp or aching, superficial	Upper chest—possibly one sided	Neck	Variable		Variable	None	
Chest wall pain	Sharp or aching	Localised	None	Variable	None	Variable	None	
Pulmonary embolism	Pleuritic	Usually lateral aspect of chest wall	None	Variable	Breathlessness, unilateral swollen leg	Sudden	Non-specific S-T changes, tachycardia	Recent trauma or surgery, venous stasis or hypercoagulability
Infection	Pleuritic or somatic	Usually lateral aspect of chest wall	None	Variable	Breathlessness, bronchi, bronchial breathing	Variable	None	URTI, cough, sputum, fever
Pneumothorax	Pleuritic	Usually lateral aspect of chest wall	Neck and back	Variable	Breathlessness	Sudden	None	COPD, trauma, tall, thin, young people
Oesophageal pain	Aching or burning	Retrosternal	Interscapular	Minutes to hours	Difficulty or pain on swallowing	Variable	None	Gastro-oesophageal reflux disease

In children over 5, erythromycin or clarithromycin may be used as a first line treatment as mycoplasma pneumonia is more prevalent in this older age group.

Arrange review within 24 to 48 hours.

Oesophageal pain

This pain is caused by acid reflux from the stomach burning the oesophageal mucosa.

The pain may be of variable onset relieved by antacids, burning in nature, radiate to between the shoulder blades, and be accompanied by swallowing difficulties. Pain may be related to eating.

Treatment is with antacids, H₂ antagonists, or proton pump inhibitors. If it does not respond to treatment, or swallowing difficulties develop, the patient should be admitted.

Beware of labelling pain as oesophageal or chest wall pain unless you have specific reasons that support this diagnosis.

Pitfalls

It is important to remember that oesophageal pain may be relieved with GTN and that some anginal pain may appear to be relieved by antacids. This is especially true of acute coronary syndrome where the pain may well be intermittent and appears to "settle".

DIAGNOSES FOR EXCLUSION

Having undertaken all of the above the flow chart (fig 6) will help you reach a diagnosis. It is vital to appreciate that included in the chart are:

- ▶ Acute coronary syndrome
- ▶ Pulmonary embolism

- ▶ Dissection of the thoracic aorta
- ▶ Pneumothorax.

Interpretation of findings

These conditions require the patient to be admitted to hospital as soon as possible and it is important that these conditions are not missed. Thus if a convincing diagnosis of a condition other than these four cannot be reached the patient should be admitted to hospital. Individual symptoms or signs are unreliable (for example, there is no guarantee that a somatic pain is not originating from the heart or that heart pain will not disappear after the administration of an antacid). It is therefore unwise to exclude the diagnosis based on a single symptom, physical sign, or investigation. Instead it should be based on several supporting pieces of information.

TREATMENT AND DISPOSAL

Treat and Refer—ACS, dissecting aortic aneurysm, pleuritic chest Pain (depending on diagnosis and condition of patient), pneumothorax, gastrointestinal pain (depending on condition of patient or not settling with appropriate treatment)

Treat and Leave—stable angina, cervical root pain, chest wall pain, pleuritic chest pain (depending on diagnosis and condition of patient), gastrointestinal pain (depending on condition of patient or not settling with appropriate treatment)

FOLLOW UP ARRANGEMENTS (IF NOT ADMITTED)

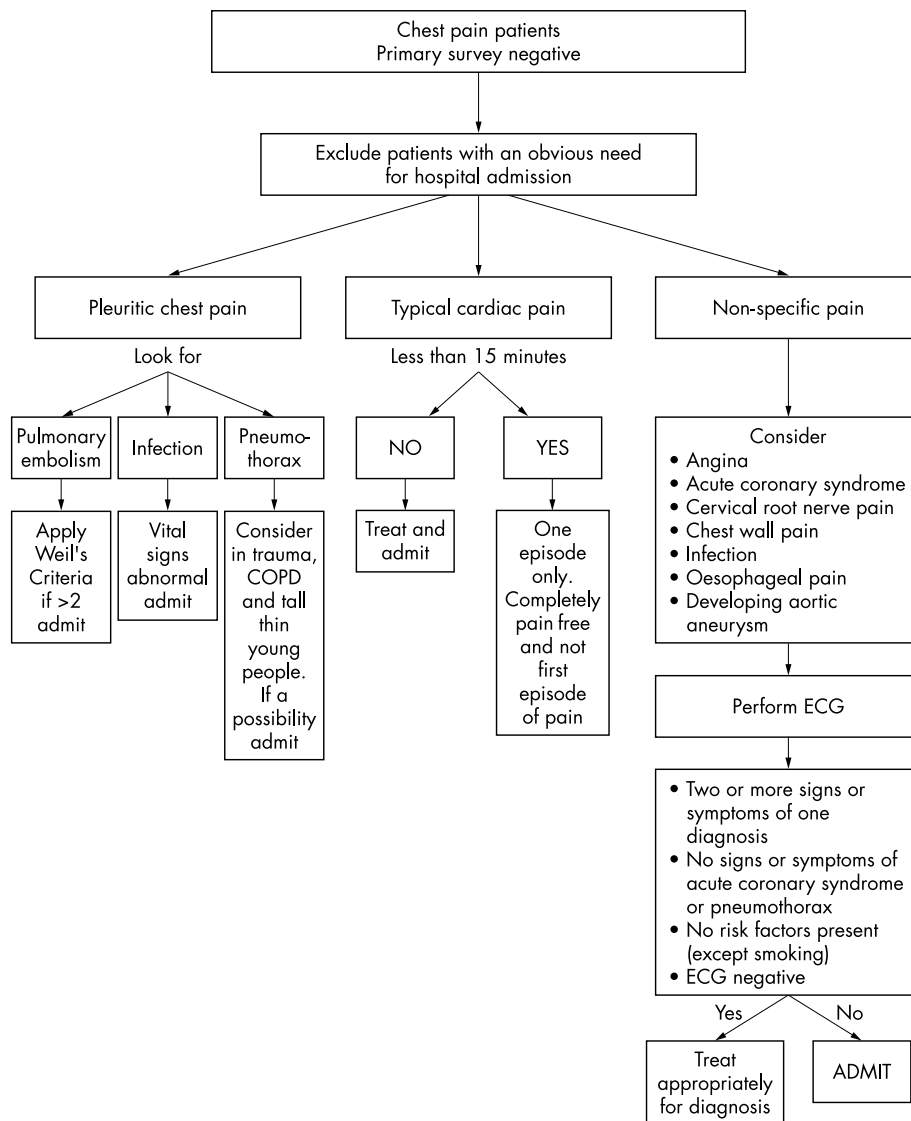
Arrange review if indicated before normal working hours or, if not, notify the responsible GP with appropriate information at the start of normal working hours.

FURTHER READING

Diagnosis

Panju AA, Hemmelgarn BR, Guyatt GH, *et al.* Is this patient having a myocardial infarction? *JAMA* 1998;**280**:1256–63.

Figure 6 Diagnoses for exclusion.



Klompas M. Does this patient have an acute thoracic aortic dissection? *JAMA* 2002;**287**:2262–72.

ECG interpretation

Foster B. *12 Lead electrocardiography for ACLS providers*. Philadelphia: WB Saunders, 1996.

Meek S, Morris F. ABC of clinical electrocardiography: introduction. I—Leads, rate, rhythm, and cardiac axis. *BMJ* 2002;**324**:415–18. (<http://bmj.bmjournals.com/cgi/content/full/324/7334/415>)

Meek S, Morris F. ABC of clinical electrocardiography: introduction. II—Basic terminology. *BMJ* 2002;**324**:470–3. (<http://bmj.bmjournals.com/cgi/content/full/324/7335/470?eaf>)

Morris F, Brady WJ. ABC of clinical electrocardiography: acute myocardial infarction—Part I. *BMJ* 2002;**324**:831–4. (<http://bmj.bmjournals.com/cgi/content/full/324/7341/831?eaf>)

Meek S, Morris F. ABC of clinical electrocardiography: acute myocardial infarction—part II. *BMJ* 2002;**324**:963–6. (<http://bmj.bmjournals.com/cgi/content/full/324/7343/963?eaf>)

Channer K, Morris F. ABC of clinical electrocardiography: myocardial ischaemia. *BMJ* 2002;**324**:1023–6. (<http://bmj.bmjournals.com/cgi/content/full/324/7344/1023?eaf>)

Heart and lung sounds

<http://www.vh.org/adult/provider/internalmedicine/lungsounds/lungsounds.html>

Auscultation Assistant. (<http://www.med.ucla.edu/wilkes/intro.html>)

Treatment

Boehringer Ingelheim. *Thrombolysis up front version 2.2*. Bracknell: Boehringer Ingelheim, May 2003.

British Thoracic Society. Guidelines for the management of community acquired pneumonia in childhood. *Thorax* 2002;**57**(suppl 1):1–24.

British Thoracic Society. Guidelines for the management of community acquired pneumonia in adults. *Thorax* 2001;**56**(suppl 4):1–64.

Joint Royal Colleges Ambulance Liaison Committee. *Guidelines version 2*. London: JRCALC Royal College of Physicians, 2002. (<http://www.asancep.org.uk/JRCALC/guidelines.htm>)

Authors' affiliations

C Laird, BASICS Scotland, Auchterarder, UK

P Driscoll, Accident and Emergency Department, Hope Hospital, Salford, UK

J Wardrobe, Accident and Emergency Department, Northern General Hospital, Sheffield, UK